



# Cervical Spinal Deformity

Flexio

*A Handbook for Patients and Health Care Providers*

120





**Scoliosis Research Society**

Dedicated to Education, Research and Treatment of Spinal Deformity

555 East Wells Street, Suite 1100

Milwaukee, WI 53202

Phone: (414) 289-9107 | Fax: (414) 276-3349

Email: [info@srs.org](mailto:info@srs.org)

To order additional brochures, please download an order form from this link:  
<http://www.srs.org/patients-and-families/patient-brochures>

Published September 2018

# Preface

---



The Scoliosis Research Society’s Adult Spinal Deformity Committee has prepared this booklet to provide patients and their families with a better understanding of cervical spinal deformity. This information is intended as a supplement to the information your physician will provide. Cervical spinal deformities may be very different from one individual to another, although a number of broad statements can be made.

Your spinal deformity surgeon will be the most important source of information for you or your child’s particular case. It is beyond the scope of this booklet to discuss technical aspects of all the various surgical procedures that may be needed, but general concepts are explained.

*It is not intended that the contents of this manual be interpreted as standards or guidelines proposed by the Scoliosis Research Society.*

# Table of Contents

---



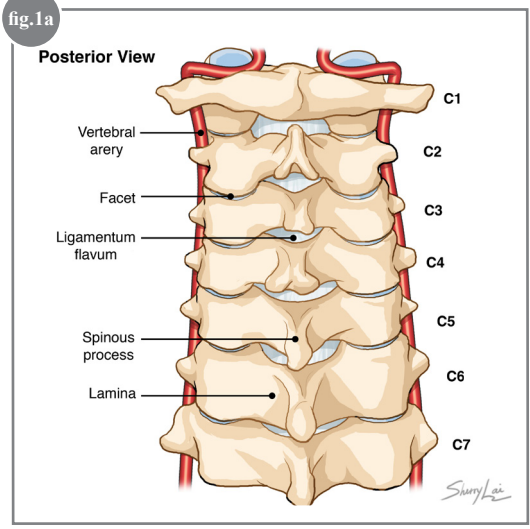
What is the Cervical Spine? .....	2
What is the Normal Cervical Alignment? .....	3
What is Cervical Deformity?.....	3
What Are the Signs of Cervical Deformity? .....	4
What Causes Cervical Deformity? .....	4
What Should Be Done? .....	5
What Factors Determine Treatment?.....	5
What Happens if the Cervical Deformity Requires Surgery? .....	6
Operative Considerations .....	7
Planning Your Surgery.....	7
Risks of Surgery .....	7
Answers to Questions Commonly Asked by Patients .....	7
Glossary of Medical Terms.....	8
Where Can I Get More Information? .....	10
Your Support Can Change the Lives of Others with Spinal Deformities.....	11



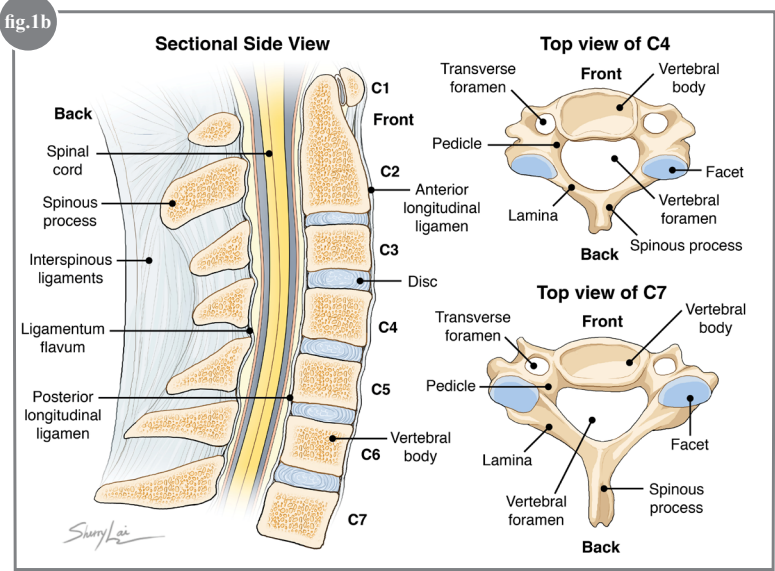
# What is the Cervical Spine?

The cervical or neck region of the spine is composed of seven vertebrae (referred to as C1 to C7; “C” for cervical) that extend from the skull to the thoracic or chest region of the spine. While the third through seventh cervical vertebrae (C3-C7, also known as the subaxial spine) are quite similar in shape, the upper cervical spine has a unique shape. The first cervical vertebra (C1) is ring shaped and helps transition the spine from the flat surface of the base of the skull. C2 has a base similar to the lower cervical vertebrae; however, has a peg that extends upwards through the ring of C1. Together, C1 and C2 are structured to provide rotatory motion (i.e. shaking one’s head as when saying “no”), with approximately half of total neck rotation coming from this level.

In the subaxial spine (C3-C7), the front (anterior) of the spine is composed of the vertebral body and disc. The back (posterior) of the spine consists of the lamina (arch of the vertebra), the spinous process (the fin that projects backwards), and the facet joints (composed of the joining of the inferior and superior articular processes). The vertebral arteries, the major posterior arteries of the brain, run through the transverse foramen of the cervical spine from C6 to C2. The spinal cord runs through the large central vertebral foramen. This anatomy is depicted in Figures 1 A and B below.



**Figures 1A & 1B:**  
 Posterior view (1A) and side view (1B) of illustrations of the cervical spine from C1 to C7. Figure 1B demonstrates the normal lordosis arc of the cervical spine and illustrates top views of the 4th cervical vertebrae (C4) and the 7th cervical vertebra (C7). The top view of C4 and C7 demonstrate the bony elements of the vertebrae, including a dedicated central hole (foramen) through which the spinal cord runs, and two smaller holes to the sides (transverse foramen) where the vertebral arteries to the brain pass.



## What is the Normal Cervical Alignment?



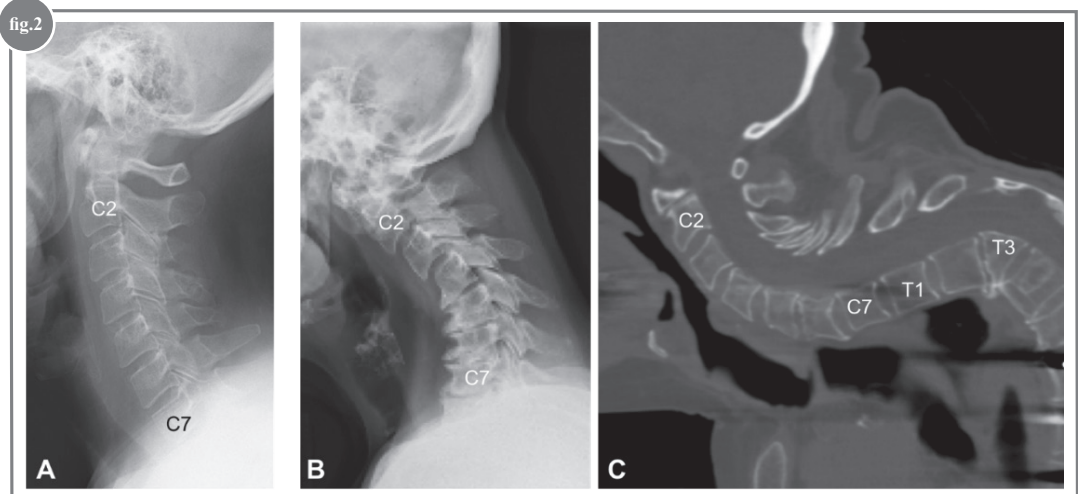
The overall normal alignment of the cervical spine, when viewed from the side (also referred to as “sagittal”) measured between C2 and C7 is approximately 15° of lordosis or arching backward. Cervical lordosis is an angular measurement of the natural curvature of the cervical spine. Normal values are patient dependent and can vary based on numerous different drivers of stability. Many conditions can affect the alignment of the cervical spine including chronic degeneration (wear-and-tear), trauma, congenital abnormalities (present at birth), and conditions that primarily affect other regions of the spine and subsequently affect the neck.

## What is Cervical Deformity?



Cervical deformity is a general term referring to any problem with alignment or orientation of the neck, ranging from the base of the skull to the thoracic spine. The neck, or cervical spine, supports the weight of the head and also allows for the widest range of motion relative to the rest of the spine. Changes in alignment may be isolated to the neck, or part of a broader change in alignment overall in the spine, such as scoliosis (curvature when looking from the front) or kyphosis (curvature bending forward when looking from the side). The neck, when viewed from the side or profile, has a normal backward arch, or lordosis, with the goals of maintaining forward gaze.

The ability to look straight ahead with normal posture, is what we have termed horizontal gaze. Changes from normal in the side view can result in rounding, or kyphosis, of the neck with the inability to hold the head up straight and achieve horizontal gaze. At its worst, this can result in chin-on-chest deformity (*Figure 2*).



**Figure 2:**

*A) An X-ray of a normal spine illustrating a smooth lordosis arc of the spine running with smooth and wide disc spaces (gap between the vertebral bodies).*

*B) X-ray showing degeneration of the middle and lower cervical discs with loss of the disc space and multiple bone spurs, leading to a significant loss of the cervical lordosis with reversal into kyphosis (arc bending forward).*

*C) MRI demonstrating maintained lordosis of the cervical spine, however, because of a severe fracture below the cervical spine at the level of T3 (note the triangular shape of the body), a significant compensatory deformity follows, leading to a chin-on-chest deformity. This demonstrates the importance of the spine below the neck on the alignment of the cervical spine.*



## What Are the Signs of Cervical Deformity?

---



1. The head and neck are tilted to one side more than the other.
2. Cervical deformity is usually accompanied by neck and shoulder pain.
3. There is an inability to stand straight without significant effort.
4. The head is tilted forward.
5. There is an inability to look straight ahead.
6. There are issues with swallowing related to head and neck posture.
7. There may be numbness, tingling and pain along with the loss of balance and coordination.
8. The head is not centered over the body when assuming a standing or upright posture.

## What Causes Cervical Deformity?

---



The most common cervical deformity is kyphosis, an abnormal forward curvature when viewed from the side. Scoliosis, sideways curvature when viewed from the front or back, can occur but is often associated with abnormal formation of bones at birth or secondary to tumors, trauma, or other abnormal curvatures in the thoracic or lumbar spine.

*The causes of cervical deformity in the side view can be broken down into several categories:*

1. **Iatrogenic:** This implies that a previous spinal surgery has left the patient with an abnormal posture. The most common form seen is in patients who have undergone a previous surgery in the back of the neck, specifically unroofing of the spinal cord at multiple levels, or laminectomy, without stabilization (screws and rods).
2. **Degenerative:** As the aging process occurs, the shock absorbers, or discs, of the spine in the neck can become dehydrated, degenerate and collapse. When this occurs, the result can be a kyphotic or pitched forward posture.
3. **Traumatic:** Patients may have injured their neck in the past and the bones and ligaments did not mend in their normal positions. Consequently, these patients can heal in a deformed or unnatural position.
4. **Congenital:** Some patients are born with abnormal fusions in their neck as a result of an underlying condition such as Klippel-Feil syndrome. The abnormal fusion can result in early degeneration and resultant cervical spinal deformity.
5. **Infections:** Severe infections of the discs can lead to destruction of the adjacent vertebral bodies resulting in a focal kyphosis of the spine. This is depicted in the illustration on the front cover of this pamphlet.
6. **Neuromuscular:** Some patients have an underlying neurologic disorder, such as Parkinson's, which can result in there being substantial imbalance across the spine secondary to abnormal muscle contraction and relaxation over time.



## What Should Be Done?

---



First-line treatment should be attempted with the goal of minimizing pain and restoring function. Common medications used for this condition include non-steroidal anti-inflammatory medication (NSAIDs), muscle relaxants, neuromodulating medications (pregabalin, gabapentin, antidepressants) and other medicines such as acetaminophens. Opioid or narcotic medication should be avoided. Other treatment options include physical therapy, chiropractic care, cervical traction, bracing, and Epidural injection therapy.

The most common reason to consider surgical intervention is progression of neurologic findings. Other reasons to consider surgery include: progression of disability and impairment in quality of life after failure of conservative treatment, worsening deformity where neck positioning results in inability to look straight ahead or results in problems with swallowing.

## What Factors Determine Treatment?

---



- 1. Deterioration in Neurologic Status*  
Patients with cervical spinal deformity frequently have associated neurologic impairment. This can be the result of compression along a nerve root causing arm pain, weakness, or numbness and tingling. Another cause of neurologic symptoms is the result of increased pressure on the spinal cord. Patients with spinal cord compression may complain of hand dysfunction, loss of coordination, deterioration of handwriting, and problems with balance during walking. When patients present with these symptoms along with evidence of spinal cord compression it is called “myelopathy.”
- 2. Level of Disability Due to Neck Deformity*  
Disability secondary to neck pain is the most common reason for a patient to seek surgical treatment. Frequently neck pain is accompanied by one or more of the factors listed below.
- 3. Degree of Deformity and Alignment in the Neck*  
Your surgeon will be carefully measuring your x-rays to understand the severity of your deformity. These measurements are used to help diagnose the problem and determine the potential types of surgery needed to address the deformity.
- 4. Documented Progression of Cervical Deformity*  
When the cervical deformity is getting progressively worse, surgery may be indicated.
- 5. Underlying Medical Problems*  
Patients with advanced disease of other organ systems such as the heart or lungs may not be considered candidates for surgery as the risk of incurring complications, including death, may be too high.

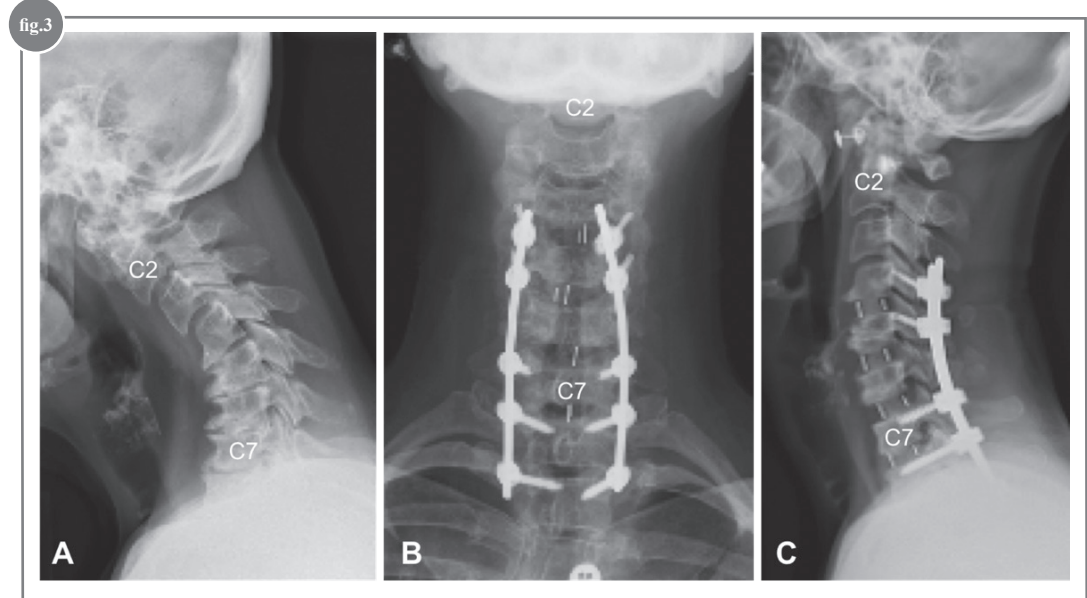


## What Happens if the Cervical Deformity Requires Surgery?

When surgery is an option to manage cervical deformity, the most common surgical procedure is a spinal fusion with instrumentation. The procedure can include surgery from the front (“anterior”), or the back (“posterior”), or a combination of both.

Anterior surgery is typically in the form of an anterior cervical discectomy and fusion (ACDF). This typically involves an incision on the front of the neck gaining access to the front of the spine. The discs that are causing the compression of the nerves and the spinal deformity are removed and replaced with a graft to correct the deformity and allow the bones to fuse, or grow together. On occasion, the complete vertebral body and adjacent discs are removed, called a corpectomy. After the discectomy and the corpectomies, a defect is created in the front of the spine that is filled with either a structural piece of bone or some other spacer (i.e. metal or plastic cage, donor bone). It is common after the space is filled to place a plate and screws on the anterior vertebrae, to maintain the position of the graft and the correction of the deformity, providing a stable environment to promote fusion.

The term “instrumentation” refers to a variety of devices used to achieve fixation in the spine. For anterior surgery, a plate and screws are the preferred fixation method (*Figure 3*). Posterior surgery uses anchors in the bone that include hooks, wires, and screws that are attached to a rod-based instrumentation system. Sometimes, in cases of severe deformity, more advanced surgical treatments are indicated, such as larger bone cuts to realign the spine (osteotomy). Furthermore, on occasion, the cervical constructs may be extended to the thoracic spine to provide a more stable base for the deformity correction.



**Figure 3:**

*A) X-ray showing cervical kyphosis.*

*B & C) Front and side view of same patient treated with an anterior removal of the discs between C4 and T1, followed by a posterior instrumentation from C4 to T2 (front view B, side view C). Note the restoration of the cervical lordosis.*





## Operative Considerations

---



*The goals of surgery are listed below:*

1. Successfully free the nerves and the spinal cord of any compression
2. Correct the cervical spine deformity and achieve balance of the spinal curvatures
3. Achieve fusion of the levels that were operated
4. Improve patient's pain and overall function

There are always risks associated with any surgical procedure. These risks should be reviewed with the patient's spine surgeon.

## Planning Your Surgery

---



Planning for spinal reconstruction is very important. It will involve you determining ahead of time who will help care for you during the early phases of recovery as well as making sure the surgery can be executed as safely as possible.

1. A preoperative conference with your surgeon with a clear understanding of expectations
2. Medical "clearance" to make sure the medical risks of surgery are minimized. This may require you to be evaluated by numerous specialties depending on the recommendation of your surgeon and primary care physician.
3. Good nutritional status before and after surgery
4. Good family and social support before undergoing life-altering surgery
5. Discontinue smoking both before and after surgery
6. Exercising program before and after surgery
7. Positive mental attitude

## Risks of Surgery

---



Despite your surgeon's extensive training and careful planning of your procedure, there are risks involved with these procedures. Risks specific to your particular procedure should be discussed with your surgeon. Further, there are different surgical options that can be used to address your deformity. Please discuss these with your surgeon so that you can make an educated decision on what procedure and which risk profile is acceptable to you.

## Answers to Questions Commonly Asked by Patients

---



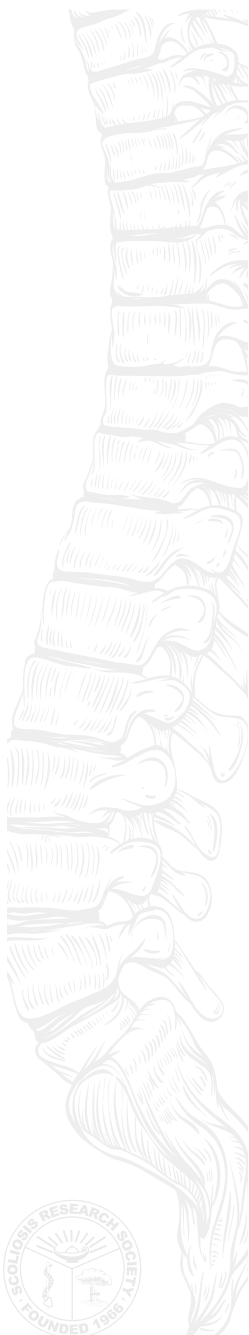1. Non-operative treatment may help the pain and some of the disability associated with the deformity, but is not a definitive treatment for the deformity.
2. You may consider surgery in the presence of neurologic deterioration or in the presence of increased pain and disability and a poor quality of life.
3. Fusing your spine will result in the absence of motion among all levels that are fused.
4. You will not be able to move your neck as you are used to once the surgery is complete and specific postoperative activity modification and bracing should be discussed with your surgeon.
5. Patient satisfaction is very high after a successful surgery and recovery. While most patients benefit from significant improvement in their pain, some pain in the neck can often persist.
6. Recovery can last 6 months to one year after the surgery.
7. If you have deterioration of your neurologic function, surgery is the preferred method to stabilize the decline in function and provide an opportunity for improvement of your condition



8. Maintaining an active lifestyle and having good nutritional habits are the best way to promote a healthy spine.
9. Smoking and anti-inflammatory medications interfere with the healing of the bone after spinal fusion procedures. These should be stopped well before the surgery and for a minimum of three months following the surgery.
10. A fused neck, especially if done at multiple levels, is not going to be a normal nor perfect neck. The goal of surgery is to make things better than they were before, with alleviation of pain and improvement of function. However, it will not be perfect; specifically, some degree of stiffness with loss of neck range of motion (depending on extent of fusion) is to be expected.

## Glossary of Medical Terms

---



**Anterior:** Nearer to the front, especially situated in the front of the body or nearer to the head

**Anterior Cervical Discectomy and Fusion (ACDF):** A surgical approach using an anterior (front of the neck) incision to remove the disc(s) of the cervical spine and fusing it with a plate and screws.

**Cervical Spine:** That portion of the vertebral column contained in the neck, consisting of seven cervical vertebrae between the skull and the rib cage.

**Cervical Traction:** A device applied to the neck that delivers traction across the cervical spine in an attempt to improve pain caused from collapse of the discs of the spine.

**Congenital:** Kyphosis or scoliosis due to bony abnormalities of the spine present at birth. These anomalies are classified as failure of vertebral formation and/or failure of segmentation.

**Chin-On-Chest Deformity:** A cervical deformity that results in the chin being stuck up against the chest. These deformities can be rigid as seen in iatrogenic deformity or flexible as seen in patients with neuromuscular causes.

**Corpectomy:** A surgical procedure that partially or completely removes a vertebral body. Typically performed to correct deformity or decompress the neurologic elements

**Decompression:** A surgical procedure where nerves are freed of compression. Usually involves a posterior approach with removal of bony structures such as the lamina.

**Degenerative:** A progressive, often irreversible deterioration of the discs and bones of the vertebral column, also known as “wear-and-tear”.

**Horizontal gaze:** The ability of the body to maintain a posture that allows for eyesight to see straight ahead.

**Iatrogenic:** Cause of spinal deformity that resulted from a previous medical or surgical intervention.

**Kyphosis:** A posterior angulation of the spine as evaluated on a side view of the spine. Contrast to lordosis. Kyphosis can be part of the normal curvature of the spine such as in the thoracic spine. When kyphosis occurs in areas it does not belong, or when it is larger than normal then it can be part of a pathologic disease state.

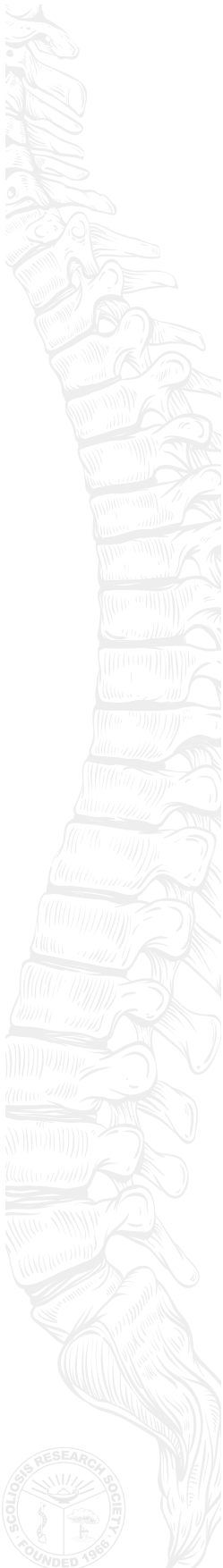**Laminectomy:** A surgical operation to remove the back of one or more vertebrae (lamina), usually to give access to the spinal cord or to relieve pressure on nerves.

**Lordosis:** An anterior angulation of the spine in the sagittal plane. Contrast to kyphosis. It is part of the normal curvature of the spine. When lordosis occurs in areas it does not belong, or when it is larger than normal then it can be part of a pathologic disease state.

**Lumbar Spine:** The portion of the vertebral column that is located below the rib cage and above the pelvis. There are typically 5 lumbar vertebrae.

**Medical clearance:** In preparation for surgery, the process by which a patient is deemed





safe to undergo surgery. This may include various tests, blood work, x-rays, and additional consultation with specialists that are specialized to make determinations regarding the safety of surgery.

**Myelopathy:** Disease of the spinal cord that is composed of symptoms of upper or lower extremity dysfunction and balance issues with walking. The diagnosis also requires radiographic confirmation.

**Nerve Root:** The initial segment of a nerve leaving the central nervous system (the spinal cord).

**Neuromuscular:** A form of cervical deformity caused by neurologic disorder of the central nervous system or muscle.

**NSAIDs (Non-Steroidal Anti-Inflammatory Drugs):** A class of drugs that targets the inflammation of cells. Non-opioid.

**Osteotomy:** The surgical cutting of bone to remove a piece that will result in correction of the spinal deformity.

**Physical Therapy:** The treatment of disease, injury, or deformity by physical methods such as massage, manipulation, heat treatment, and exercise rather than by drugs or surgery.

**Posterior:** Further back in position; of or nearer the rear or hind end, especially of the body or a part of it

**Progression:** The worsening of a spinal deformity or other condition over time.

**Radiculopathy:** A set of conditions that result in a nerve not functioning properly. The result is typically either pain, numbness/tingling, and/or weakness

**Scoliosis:** Lateral deviation of the normal vertical line of the spine which, when measured by x-ray from a front view, is greater than ten degrees. Scoliosis consists of lateral curvature of the spine with rotation of the vertebrae within the curve

**Spinal Cord:** A soft bundle of nerves that extends from the base of the brain to the lower back. It is the connection of nerve tissue that transmits signals from the brain to the rest of the body as well as gathering information from the body and providing feedback to the brain.

**Spinal Instrumentation:** Metal implants fixed to the spine to improve spinal deformity while the fusion matures. This includes a wide variety of rods, hooks, wires, bands, plates, spacers and screws in various combinations.

**Spinal Fusion:** A technique of stabilizing two or more vertebrae by bone grafting

**Thoracic Spine:** The vertebral column that exists within the levels of the rib cage. There are typically 12 thoracic vertebrae

**Traumatic Deformity:** Spinal deformity that results secondary to a history of trauma to the bones or ligaments of the spinal column.



## Where Can I Get More Information?

---



The best information about your specific condition typically comes directly from your surgeon. You can check to see if your surgeon is a member of the Scoliosis Research Society by going to <http://www.srs.org/find/>. Membership in SRS indicates that at least 20% of the doctor's practice is in spinal deformity, that they attend annual meetings, and stay abreast of new information and new research.

In addition to the Scoliosis Research Society's website ([www.srs.org](http://www.srs.org)), there are other reputable organizations that may offer information about cervical spinal deformities.

Below is a list of a few patient resource websites that may be of assistance:

- [www.srs.org](http://www.srs.org) – Scoliosis Research Society
- [www.posna.org](http://www.posna.org) - Pediatric Orthopaedic Society of North America
- [www.aaos.org](http://www.aaos.org) – American Academy of Orthopaedic Surgeons
- <http://etext.srs.org/> - SRS provides information through the E-Text as an educational service. E-Text material is not intended to represent the only, nor necessarily best, methods or procedures appropriate for the medical situations discussed, but rather is intended to present an approach, view, statement or opinion of the chapter author(s) that may be helpful to others who face similar situations. SRS disclaims liability for all claims that may arise out of the use of techniques demonstrated therein by such individuals.

# Your Support Can Change the Lives of Others with Spinal Deformities



Please consider a donation to SRS.

100 percent of all contributions and donations to the Scoliosis Research Society's (SRS) Research, Education Outreach (REO) Fund are used entirely for research, outreach programs, and educational scholarships and fellowships seeking improved treatments, the causes and possible prevention of spinal deformities. Operating funds for SRS come from membership dues, educational meetings and courses, publication sales and other sources.

With your support, SRS can continue to support and offer necessary educational opportunities, beneficial research grants and maintain effective advocacy efforts that will change the lives of those living with spinal deformities.

If you would like to make a donation to the Scoliosis Research Society, please fill out the form below and mail it to:

Scoliosis Research Society  
555 East Wells Street, Suite 1100  
Milwaukee, WI 53202-3823 USA

Please make checks payable to Scoliosis Research Society.

If you would like to make your donation online, please go to [www.srs.org/professionals/research-and-journal/donate](http://www.srs.org/professionals/research-and-journal/donate)

**YES!** I would like to donate to the Scoliosis Research Society (SRS) to help continue in fulfilling its mission to improve the lives of patients with spinal deformities!

Enclosed is my gift of:  \$10,  \$20,  \$35,  \$50,  \$100,  \$150,  Other \_\_\_\_\_

This gift is (in honor/in memory) of \_\_\_\_\_

Please make checks payable to Scoliosis Research Society. If you would like to make your donation online, please go to <http://www.srs.org/professionals/research-and-journal/donate>

### *Credit Card Information*

Name \_\_\_\_\_

Address \_\_\_\_\_ City \_\_\_\_\_ State \_\_\_\_\_ Zip \_\_\_\_\_ Country \_\_\_\_\_

Phone \_\_\_\_\_ Email \_\_\_\_\_

\_\_\_\_\_  
Visa, MasterCard, American Express, Discover

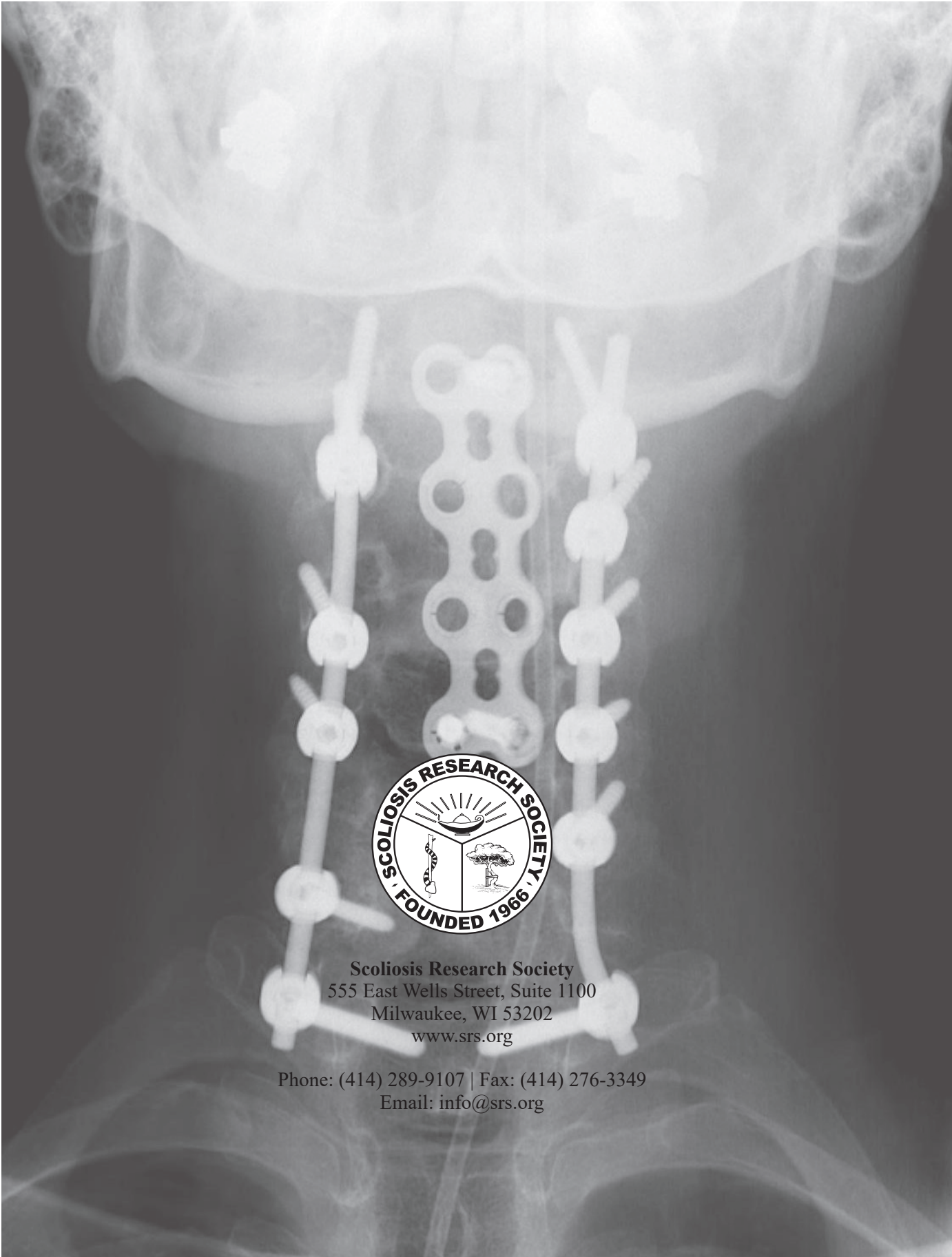
Card Number \_\_\_\_\_

Exp. Date (MM/YY) \_\_\_\_\_

Signature \_\_\_\_\_







**Scoliosis Research Society**  
555 East Wells Street, Suite 1100  
Milwaukee, WI 53202  
[www.srs.org](http://www.srs.org)

Phone: (414) 289-9107 | Fax: (414) 276-3349  
Email: [info@srs.org](mailto:info@srs.org)