



# **The Wilmington Brace in the Treatment of Adolescent Idiopathic Scoliosis**

Glenn E. Lipton, M.D.  
J. Richard Bowen, M.D.



Address all correspondence to:

J. Richard Bowen, M.D.  
Chairman, Department of Orthopaedic Surgery  
The Alfred I. duPont Hospital for Children  
1600 Rockland Road  
Wilmington, DE 19899

## Introduction:

In children with Idiopathic Scoliosis and curves between 25 and 39 degrees the recommended treatment is bracing. The goal of the bracing regimen is to arrest the progression of the curve. Historically the first braces used to treat scoliosis acted passively to correct the deformity of the spine. With the introduction of the Milwaukee brace, a cervico-thoraco-lumbo-sacral orthosis, both passive and active corrective forces were employed to halt the progression of the curve<sup>4</sup>. While good results were observed with the Milwaukee brace, patient compliance with brace wear was problematic due to its' bulky construct. To improve patient compliance substantially less bulky and lightweight thoraco-lumbo-sacral orthoses were developed. G. Dean MacEwen, M.D. at the Alfred I. duPont Institute developed the Wilmington brace also known as the duPont Brace. Long-term studies have shown that with the less bulky Wilmington brace similar results are obtained when compared to patients treated with the Milwaukee brace<sup>1,3,5,6,9</sup>.

The Wilmington Brace is a custom-made plastic underarm thoraco-lumbo-sacral orthosis used for the non-operative treatment of idiopathic scoliosis and certain other spinal disorders. The brace is a total-contact orthosis and is fabricated from one of several plastics with the most common being Orthoplast. The brace is designed as a body jacket, which opens in the front for easy removal and is held closed by adjustable Velcro straps. The top trim lines are established to fit high in axillae and the inferior trim lines are at the levels of the greater trochanters and the pubic symphysis. Corrective molds are fabricated into the plastic of the body jacket for correction of the spinal deformity. Since the brace is thin it can be hidden under the clothing. (Fig. 1)



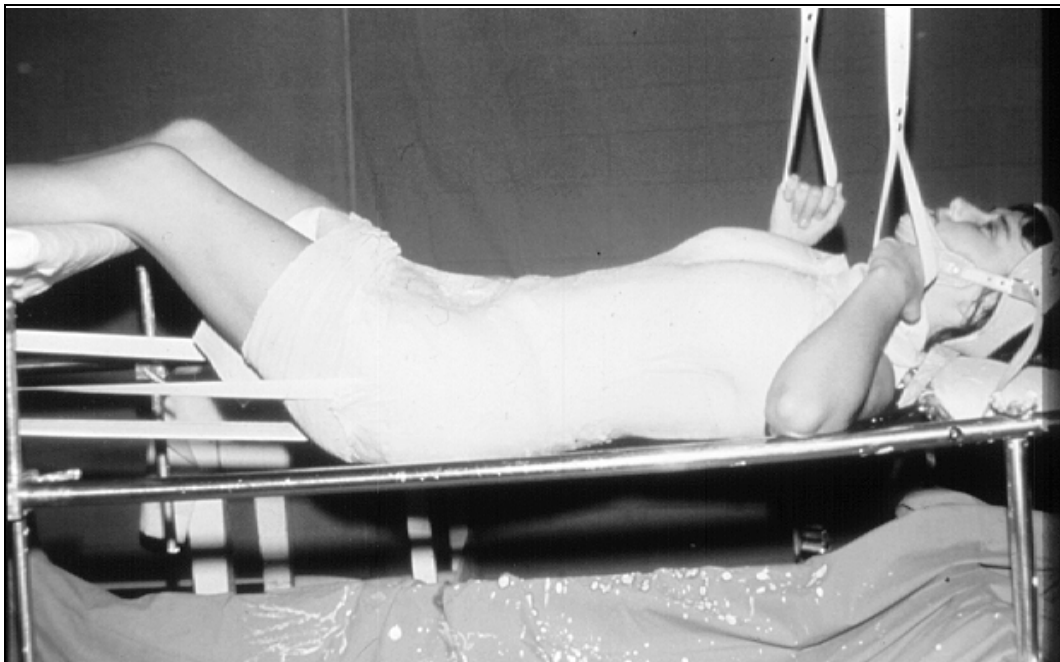**Figure 1.** The Wilmington Brace is a lightweight thorac-lumbo-sacral orthoses with adjustable straps.

## **The First Wilmington Brace:**

In 1969, Dr. G. Dean MacEwen evaluated a girl with adolescent idiopathic scoliosis at the Alfred I. duPont Institute in Wilmington, Delaware. His treatment recommendations included the use of a Milwaukee brace; however, the patient "refused" the Milwaukee brace in spite of extensive counseling. The patient was given another option, placement in a Risser localizer plaster cast, which would need to be changed every three to four months until she reached skeletal maturity. The patient again "refused" the cast treatment but agreed to wear a brace if she could take it off to bathe and if it would fit inconspicuously beneath her clothes. With the concept of a low profile and removable body jacket; a brace was defined and fabricated from Orthoplast, a thermoplastic material. In the fabrication process the patient was placed in a Risser localized corrective cast which was then removed and used as a mold to fabricate the total contact plastic brace. The patient wore the brace 23 hours per day until she reached skeletal maturity. The progressive scoliosis was halted and the patient was weaned from the brace. She is periodically reevaluated and has shown no adult progression of the curve.

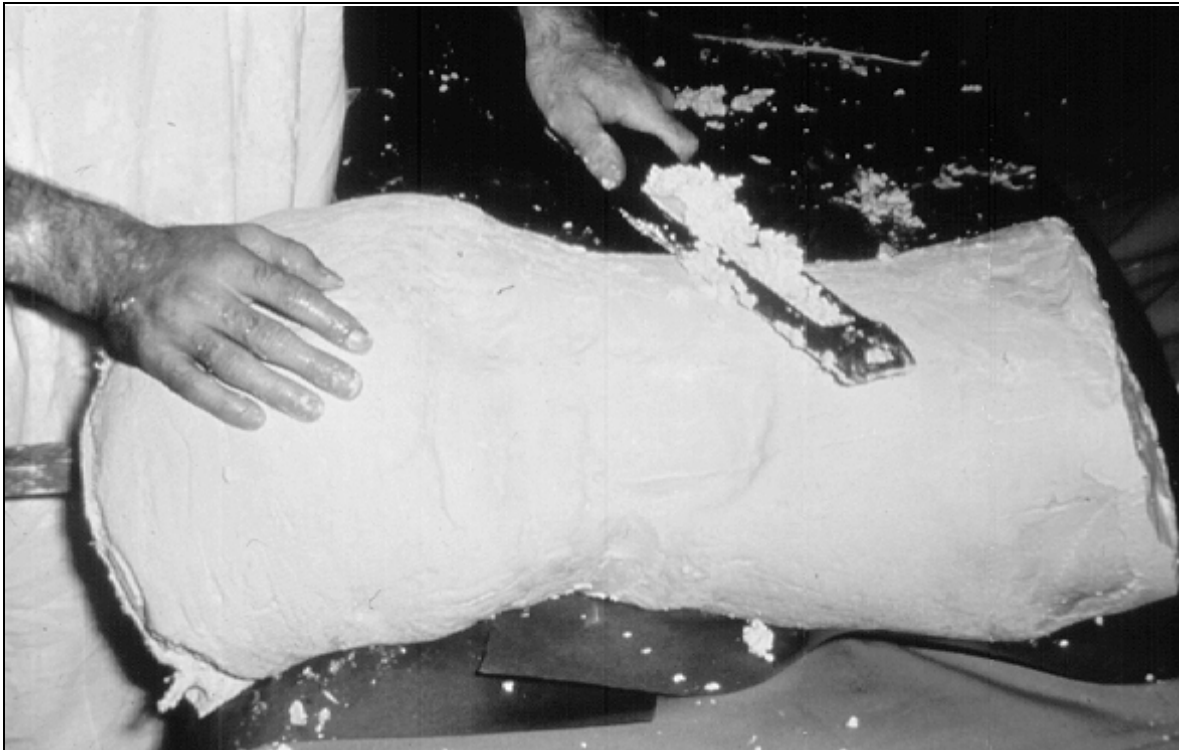### **Technique of fabrication:**

To fabricate the Wilmington brace it is necessary to provide a positive mold (plug) such that the thermoplastic material may be shaped around a rigid and exact form. To make the positive mold a Cotrel or Risser type cast is applied (negative mold) with the patient in supine position on a cast table. At the time of application of the cast, both longitudinal and transverse reduction forces are applied with the goal of achieving as much clinically observed improvement of the deformity alignment as possible<sup>4</sup>. Longitudinal traction is applied by a head halter and a pelvic halter (Fig.2).



**Figure 2.** Application of Risser cast, with longitudinal traction in place.

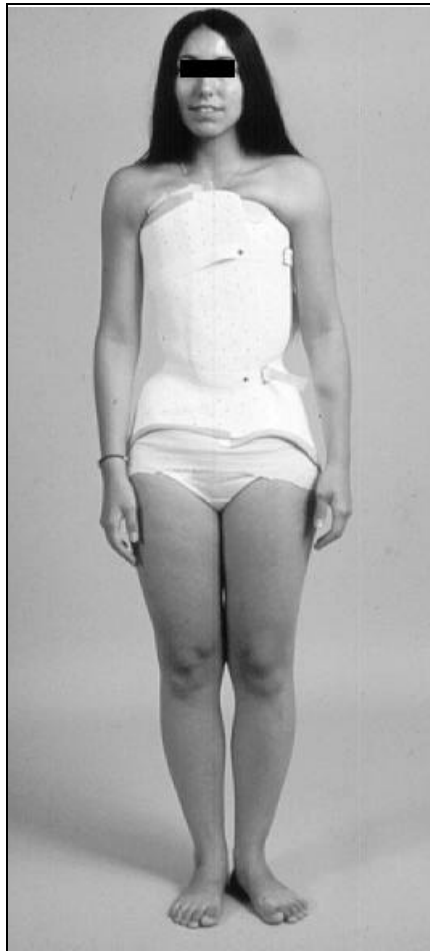The transverse reduction forces are applied by Cotrel straps or by hand pressure in the Risser cast. With the patient in the cast, a roentgenogram is made to determine the amount of reduction of the curve and the degree of improvement of the alignment and balance. If the correction is adequate, the cast is removed from the patient and then filled with plaster to provide the positive mold. The positive molds may be further modified to refine the positioning of the reduction forces and eliminate areas, which produce pressure points (Fig. 3).



**Figure 3.** Modification of the positive mold (plug).

After the positive mold has been refined, thermoplastic brace material is shaped to the positive mold and overlapped in the front to allow anterior opening of the brace. Three commonly used thermoplastic materials used in brace production include: Orthoplast, polypropylene, or Vitrethene.

The brace is fit to the patient by establishing trim lines at the level of the greater trochanters and the pubic symphysis inferiorly, and the superior aspect of the brace is trimmed to fit high in the axillae (Fig. 4). The inferior trim lines should allow the patient to sit comfortably with the hips flexed. The front is contoured to allow about two inches of overlap at the anterior opening. Adjustable Velcro straps allow easy closure (Fig. 1). A final roentgenogram is made with the patient wearing the orthosis to verify curve reduction. The patient is instructed to wear a cotton undergarment under the plastic brace to prevent skin irritation. Typically, most teenage patients will outgrow the brace in approximately one year at that time re-fitting is necessary for ideal curve treatment.



**Figure 4.** A well fit brace with trim lines at the level of the greater trochanters and the pubic symphysis inferiorly, and the superior aspect of the brace is trimmed to fit high in the axillae.

Some advantages of the Wilmington Brace are the time of fabrication is considered to be about 50% less than the Milwaukee brace and the cost averages about 40% less than the Milwaukee brace. At the Alfred I. duPont Institute, most patients can receive the finished brace on the same day of the casting.

**Indications for brace treatment:**

The indications for treating adolescent idiopathic scoliosis with the Wilmington Brace are similar to those for the Milwaukee brace<sup>4</sup>. The patient should be skeletally immature as assessed by Risser sign and onset of menarche. The ideal Risser sign at the time of treatment should be 2 “+” or less and the onset of menarche should be no more than six months from the start of brace treatment.

The magnitude of the curve is also a major consideration. Curves between 25 and 39 degrees are recommended for bracing.

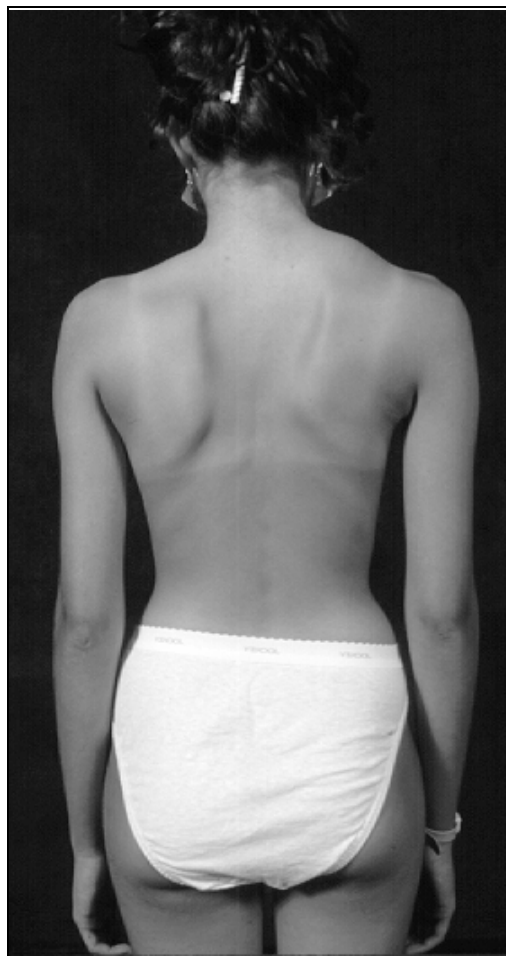
The Wilmington brace is a thoraco-lumbo-sacral orthosis, which should only be used to treat select curve types. The types of curves that are successfully treated with the thoraco-lumbo-sacral orthosis are lumbar, thoracolumbar and low thoracic curves with an apex below the seventh thoracic vertebra.

Flexibility of the curve is an important consideration. If the curve is flexible and reduces in the brace to at least a 50% reduction, the chance for successful halting of the curve progression is greater. Rigid curves, with reduction of the curve less than 50%, have a poorer outcome.

Another important consideration in the treatment of adolescent idiopathic scoliosis, not only with the Wilmington brace but with all braces is the cooperation of the patient who is prescribed brace wear.

### **Contraindications for brace treatment:**

One contraindication for brace treatment of adolescent idiopathic scoliosis is skeletal maturity. A Risser sign at the time of treatment of 3 or higher is a contraindication and the onset of menarche more than six months for the start of brace treatment is a contraindication. In general if there is less than six months of growth left the brace treatment is contraindicated.

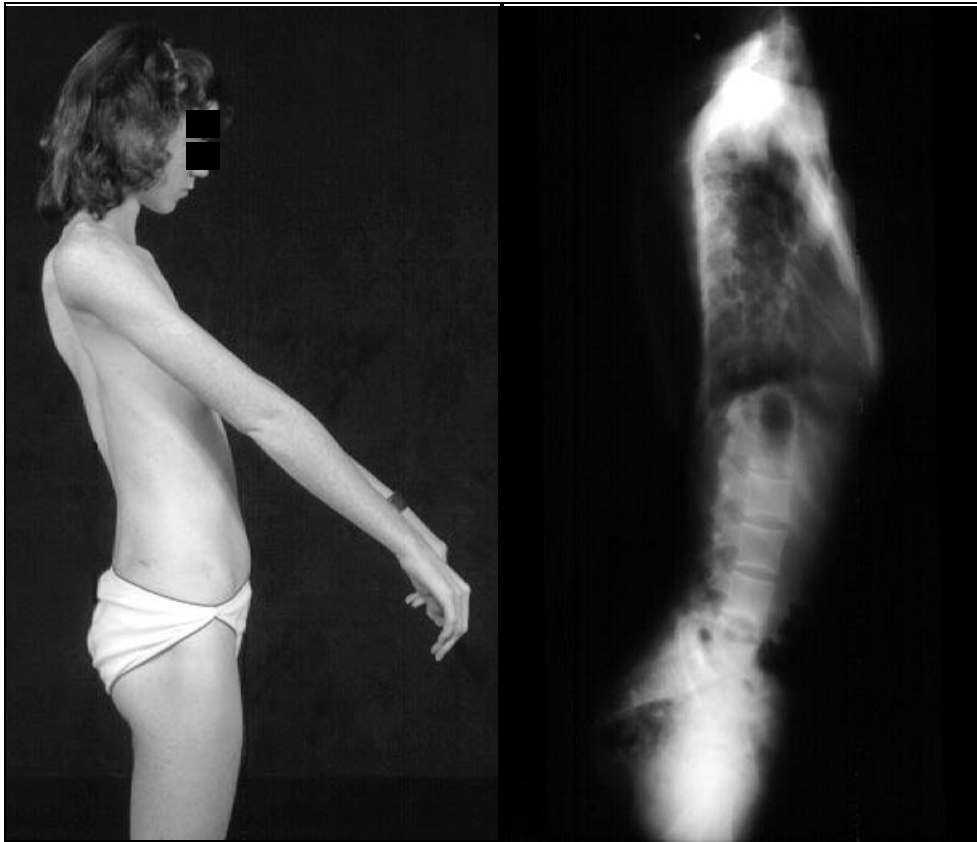

**Figure 5.** A high thoracic curve should not be treated in a thoraco-lumbo-sacral orthosis.

High magnitudes of the deformity are also a contraindication. Curves greater than 40 degrees do not respond well to bracing.

Another contraindication of the thoaco-lumbo-sacral orthosis is a high thoracic curve with an apex above the seventh thoracic vertebrae. This condition is not well treated since the highest contact points of the brace are under the arms and they can't create the appropriate reduction forces to address the high thoracic curves (Fig. 5). In these cases a Milwaukee brace is recommended for treatment. Severe lordosis is also not adequately treated in the thoaco-lumbo-sacral orthosis (Fig. 6).

The reduction molds in the brace may exert posterior forces on the spine and exaggerate the lordosis. In patients with lordosis, the reduction molds can be placed laterally; however, the brace should be used with caution.



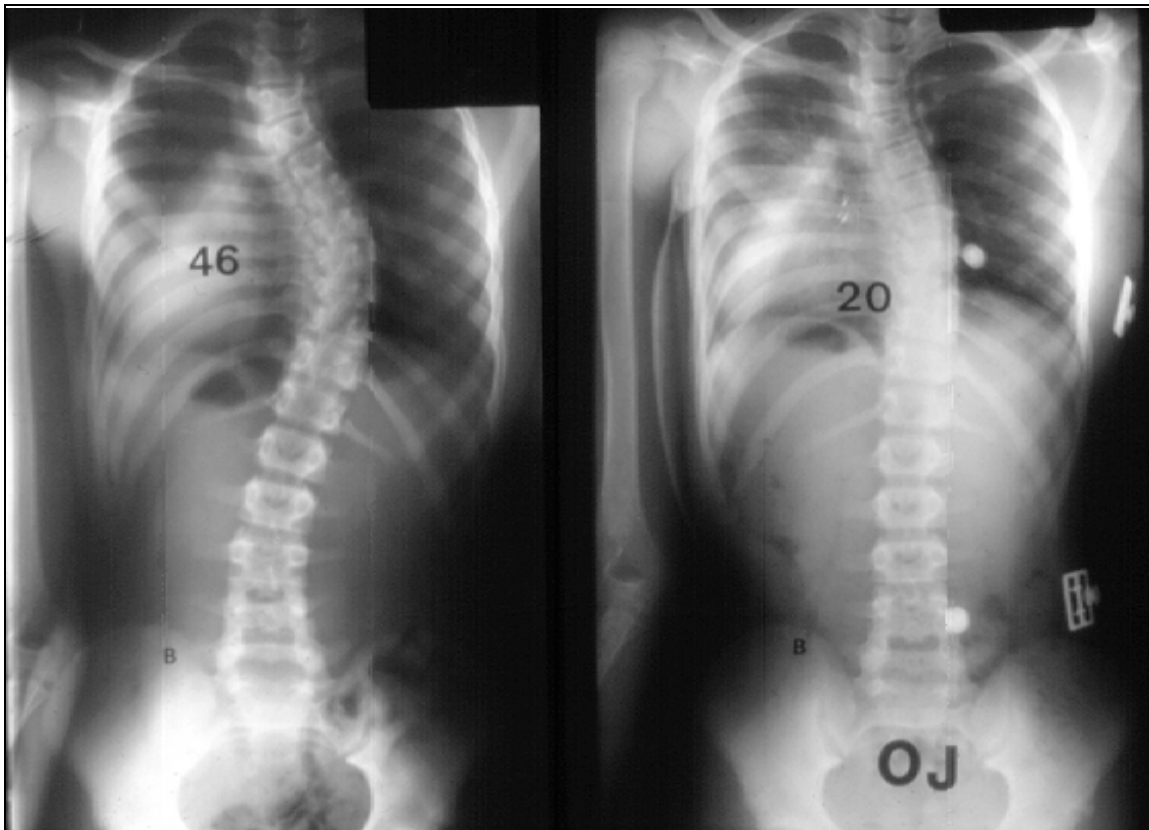
**Figure 6.** Severe thoracic lordosis should not be treated in a thoraco-lumbo-sacral orthosis

Severe rigidity of the curve is an important contraindication for brace use. If the curve is rigid, and the brace is unable to produce or maintain the reduction, poor results are expected.

Respiratory insufficiency is also a contraindication. In a study of twenty-five patients, the vital capacity was decreased initially by 18 percent when the brace was applied; however, the result was temporary. At maturity, the patients had normal vital capacities and no restriction of pulmonary capacity.

### Follow up and Patient Management:

When patients are first fitted with the Wilmington brace, there is an initial adjustment period, which usually lasts 5 to 10 days. The patient is prescribed to wear the brace a specific number of hours per day. Initially, the Velcro straps are left slightly loose so the patient may adjust slowly to the brace. Daily the straps are increasingly tightened until the appropriate level of snugness is reached. If any areas of tenderness or skin irritation develop, the patient's brace is adjusted for optimal fit. Roentgenograms are made after one month with the patient wearing the brace to verify the fit of the brace and determine the degree of curve reduction. To follow progression of the curve repeat roentgenograms should be made approximately every six months with the brace removed (Fig. 7). No further roentgenograms are required with the patient wearing the brace since all reduction is achieved at the time of the initial fitting. If any major adjustments are made to the brace, a roentgenogram is necessary to verify position.



**Figure 7.** Follow-up roentgenogram of patient without brace (left) and with brace on (right).

Most activities and exercises are unrestricted during treatment. However, the patient should be cautioned against unsafe activities, including activities, which may cause extreme arching, bending or twisting of the torso and trunk.

The prescribed daily hours of brace wear is typically 23 hours per day; however, recent studies have shown 16 hours per day is satisfactory in most patients. Most orthopaedists at this Institution prescribe brace use of 16 hours per day in curves less the 35 degrees and 23 hours per day in curves



between 35 and 40 degrees. We believe the correction is dependent on time in the brace, the more the brace is worn the better the outcome. When the patient reaches skeletal maturity the brace weaning begins. Skeletal maturity is determined by the finding of a Risser sign of 4, being greater than 12 months post menarchal, and by lack of growth in height.

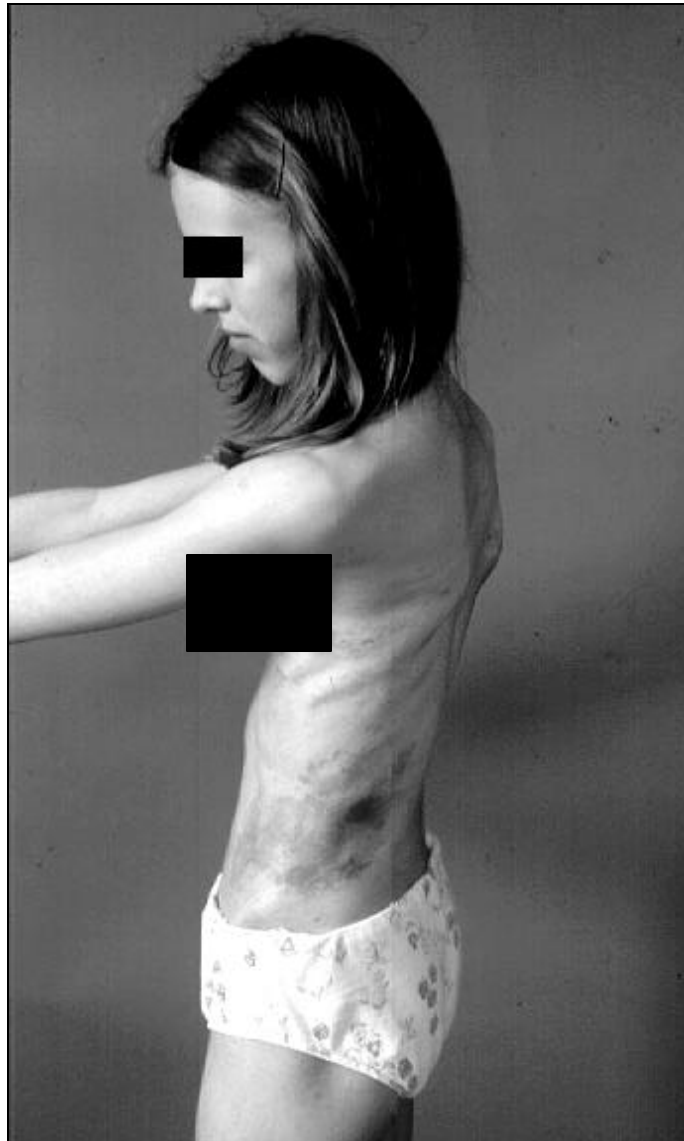At brace weaning, the patient's time of brace wear decreases two hours a day for two consecutive months. After this first phase of weaning, a roentgenogram is made of the patient without the brace. If the spine remains stable then brace weaning continues with the time of brace wear decreasing another two hours a day for two months. After the second phase of weaning, another roentgenogram of the patient without the brace is made to verify the stability of the spine. If stability is maintained then the weaning program continues following the above steps until the patient is completely independent of the brace. If at any time during the weaning process the stability of the spine is in question, the bracing regime is continued. If the spinal instability occurs at the beginning of weaning then full-time bracing is reinstated. If the instability occurs during the weaning process, the bracing should continue. In these cases the child should continue wearing the brace the amount of time which maintained spinal stability.

The main problem with many forms of the spinal orthoses for treatment of spinal deformity is patient compliance. The Wilmington brace offers several advantages over other braces in that its' wear or patient use is easily determined. When a patient is compliant with the brace wear thin brown callosities will develop in the skin over both anterior superior iliac spines and over the reduction molds. In addition to the callosities, slight compression of the lower ribs can be seen on most roentgenograms of the spine, and the brace will exhibit signs of wear. If none of the characteristics of use develop, the patient should be counseled about their lack of compliance. Current studies have employed the use of compliance monitoring by both pressure and temperature sensors. This technology is now affordable and may increase compliance of the brace wear, by allowing the treating physician to counsel those children who are not using the brace as prescribed<sup>2</sup>.

### **Complications of Wilmington Brace Treatment:**

Problems encountered due to the treatment with the Wilmington Brace include skin irritation, temporary decrease in vital capacity, mild chest wall and inferior rib deformation.

The skin irritation is a common problem. To reduce the likelihood or occurrence of the skin irritation frequent changing of the cotton undergarment should occur. In addition close attention should be paid to size of the undergarment. If the undergarment is too large and the fabric of the garment "bunches" or folds up in a particular spot it may also lead to irritation. In warm climates and in the summer months there is an increase in occurrence of skin irritation due to the increase in heat and sweat. To alleviate the mild irritations the Velcro straps may be loosened for several days to reduce force, which helps prevent pressure areas. If a localized area of skin irritation persists, the brace can be modified to relieve the pressure. To discontinue the bracing treatment due to skin irritation is uncommon; however, in our experience we have seen two patients who developed such a severe "atopic dermatitis" which necessitated termination of the brace treatment (Fig. 8).



**Figure 8.** Severe atopic dermatitis developed on the trunk of this girl.

The vital capacity may be temporarily reduced in patients treated with the Wilmington brace, therefore the orthosis is not recommended for patients with severe respiratory insufficiency. As previously reported from this Institution, 26 patients undergoing brace treatment had their vital capacity reduced by an average of 18 per cent when wearing the brace compared to their vital capacity when the brace was not worn. Further, no negative effects to the pulmonary function were found to occur in patients undergoing long-term treatment of greater than three years<sup>5</sup>.

The brace is a total contact orthosis and pressure is applied over the chest wall, breast, and lower ribs. While no adverse affects to breast development have been observed, the lower rib cage may change. The changes are mild, yet still apparent while the patient is under treatment. At the end of treatment when brace use is discontinued the mild rib cage deformity disappears. No severe permanent chest wall deformities have developed.

## Results of Wilmington Brace Treatment:

Six major studies have been undertaken at the Alfred I. duPont Hospital for Children reporting our experience with Wilmington Brace treatment for adolescent idiopathic scoliosis<sup>1,2,3,5,6,9</sup>. In 1980, Bunnell, MacEwen, and Jayakumar reported the outcomes of the first 48 patients to complete the Wilmington brace treatment program<sup>5</sup>. In 42 of the 48 patients, the curve progression was halted. In this preliminary study two factors were identified in the prognosis for treatment of a given curve. The first factor identified was the flexibility of the curve in terms of the maximum reduction obtained when in the brace. The second and most important prognostic factor is the degree of curvature at the beginning of treatment. They authors conclude when the indications are adhered to the Wilmington brace is as effective as the Milwaukee brace in the maintenance of reduction and halting the progression of the curve.

In 1986, Bassett, Bunnell, and MacEwen<sup>3</sup> reported the outcome of 79 patients with 95 curves treated with the Wilmington brace and having an average follow-up of 2 years and 6 months after treatment<sup>2</sup>. The patients' inclusion criteria for the study included a pre bracing curve of 20 to 39 degrees and a Risser sign of zero or one. They considered twenty-seven of the ninety-five curves failures due to their progression of more than five degrees at follow-up, however of those who were considered failures only 10 progressed enough to warrant fusion. Lonstein and Carlson<sup>5</sup> reported progression without treatment in 68%, and Bassett concluded, "the Wilmington brace favorably alters the natural history of 20 to 39 degree idiopathic curves in skeletally immature patients."

In a 1990 long-term follow-up study, Piazza and Bassett<sup>9</sup> evaluated curve progression after completion of Wilmington Brace treatment for scoliosis in 67 patients. Their patient inclusion criteria were the same as the previous Bassett et al.<sup>3</sup> study with follow-up ranging from 5 to 13 years. In this study the authors found sixteen patients (21%) had curve progression of 1 to 14 degrees after the brace treatment was discontinued with nine (12%) patients requiring spinal fusion.

In 1996, Allington and Bowen reported the results of 188 patients treated for adolescent idiopathic scoliosis<sup>1</sup>. Ninety-eight patients wore the Wilmington brace 23 hours per day for treatment, which was considered full-time brace wear. Forty-nine patients wore the brace 16 hours per day, which was considered part-time brace wear. Forty-one patients had electrical stimulation and were considered a control group since this method of treatment is considered to be ineffective<sup>6</sup>. The authors concluded that the difference in progression between both the full-time and part-time bracing programs and the electrical stimulation was significant ( $p < 0.05$ ). The difference in progression between full-time and part-time bracing was not significant ( $p > 0.05$ ). Therefore, the Wilmington brace is believed to be effective in preventing progression of curves of 40 degrees or less in skeletal immature patients who have adolescent idiopathic scoliosis.

In a current review by Gabos et al.<sup>6</sup>, the authors evaluated all girls between 1973 and 1983 who successfully completed a course of full-time (23 hours per day) treatment with the Wilmington brace for adolescent idiopathic scoliosis measuring between 20 and 45 degrees at this Institution. The mean age at follow-up was 31 years. It was found that 13 percent demonstrated curve progression of 5 degrees or more. However, no curve progressed more than 10 degrees from the curve measured at

initial treatment. The authors conclude that the majority of the curves do not progress, but a spinal radiograph in the third or fourth decade of life is recommended to monitor the status of these curves.

Most recently, Bowen et al,<sup>2</sup> evaluated the compliance of patient bracing utilizing an objective compliance monitor in the form of a temperature sensor. They reported the overall compliance at 75 % as measured by the objective monitoring. When the compliance was calculated from the patients' reported hours of brace use the compliance was calculated at 85 percent. There was a negative correlation between age and compliance with 10, 12, and 14 year old patients having mean compliance of 84 percent, 77 percent, and 60 percent respectively. And there was no difference in wear compliance between children with 8 hour, 12 to 16 hour and 23 hour bracing regimens. The authors conclude that younger children are more compliant, all bracing regimens have the compliance and there is a need for objective compliance monitoring to accurately evaluate the brace use.

### **Summary:**

The Wilmington brace was developed by G. Dean MacEwen at the Alfred I. duPont Institute for the treatment of adolescent idiopathic scoliosis. It is an underarm, total-contact, plastic body jacket which has been shown to be effective in arresting the progression of curves in adolescent idiopathic scoliosis when the indications are carefully adhered to.

### **References:**

1. Allington, N.J. and Bowen, J.R.: Adolescent Idiopathic Scoliosis: Treatment with the Wilmington Brace. *J. Bone and Joint Surg.* 78-A: 1056-1062, July, 1996.
2. Bowen, J.R.; Takemitsu, M.; Rahman, T.; Glutting, J.; Scott, C.B.: Compliance Monitoring of Brace Treatment for Patients with Idiopathic Scoliosis. In submission.
3. Bassett, G. S.; Bunnell, W. P.; and MacEwen, G. D.: Treatment of Idiopathic Scoliosis with The Wilmington Brace. Results in patients with a Twenty to Thirty- nine-degree Curve. *J. Bone and Joint Surg.*, 68-A:602-605, April 1986.
4. Blount, W. P., and Moe, J. H.: *The Milwaukee Brace*. Baltimore, Williams and Wilkins, 1973.
5. Bunnell, W.P.; MacEwen, G.D.; and Jayakumar, S.: The Use of Plastic Jackets in the Non-operative Treatment of Idiopathic Scoliosis: Preliminary Report. *J. Bone and Joint Surg.*, 62-A:31-38, Jan. 1980.
6. Gabos, P.G.; Bojescul, J.A.; Keebler, K.; Rich, L.; Bowen, J.R.: Long-Term Follow-up of Adolescent Idiopathic Scoliosis in Females Treated with the Wilmington Brace. Accepted with revisions to the *J. Bone and Joint Surg*

7. Lonstein, J. E.; and Carlson, J. M.: The Prediction of Curve Progression in Untreated Idiopathic Scoliosis During Growth. *J. Bone and Joint Surg.*, 66A: 1961-1071, Sept. 1984.
8. O'Donnell, C. S.; Bunnell, W. P.; Betz, R. R.; Bowen, J. R.; and Tipping, C. R. Electrical Stimulation in the Treatment of Idiopathic Scoliosis. *Clin. Orthop.*, 229:107-113,1988.
9. Piazza, M. R.; and Bassett, G. S.: Curve Progression after Treatment with the Wilmington Brace for Idiopathic Scoliosis. *J. Pediat. Orthop.*, 10:39-43,1990.